THE APAC TIMES

Emerging Innovations in Cancer Immunotherapy

FEBRUARY 2020 Edition 1, Volume I

Substantial Tumor Regression In Prostate Cancer Patient With Extensive Skeletal Metastases Upon Immunotherapy (APCEDEN®)

This study presents a case of ***metastatic prostate adenocarcinoma*** and the tumour remission observed after administration of APCEDEN® - a personalised Dendritic cell based Immunotherapy. Safety, efficacy and efficiency of the therapy were monitored throughout the treatment regime.

A 58 years old Caucasian male diagnosed with prostate adenocarcinoma with GLEASON score 8. The subject received chemotherapy (Zytiga and Lupron) and hormonal treatment, but represented a refractory pattern after multiple chemo failures, with PSA levels rising above 200ng/ml. The timeline of treatment taken is summarized in **Figure 1**.

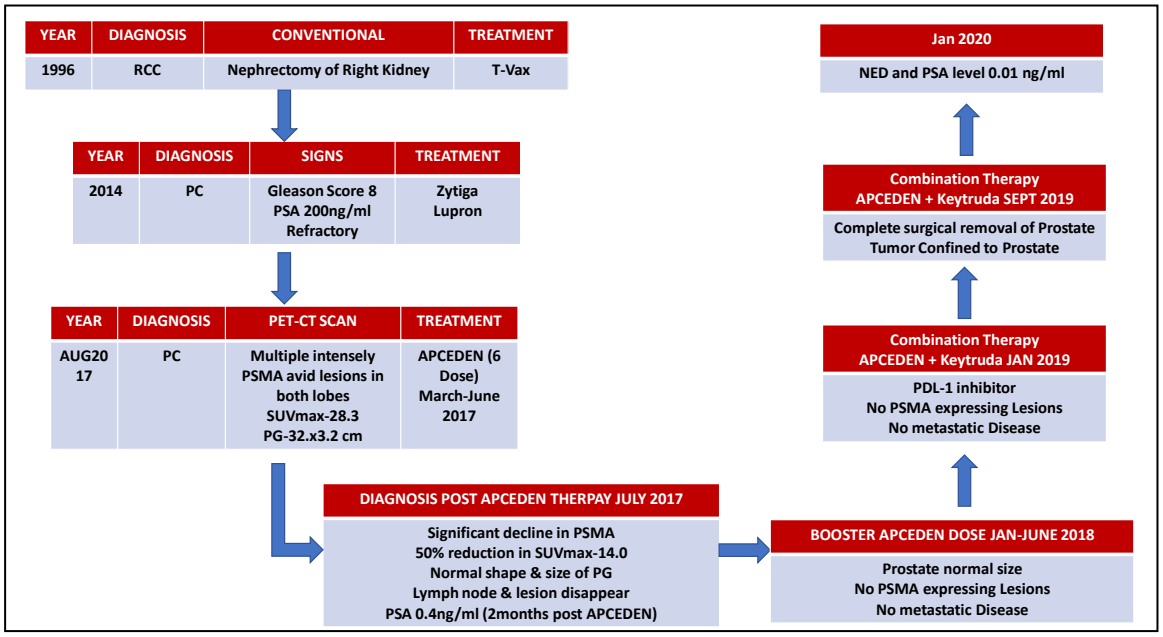

Figure 1: *Flow chart depicting patient's timeline of cancer treatment.*

After exhausting conventional treatments including multiple chemotherapies and hormone therapy, the patient was administered autologous Dendritic Cell immunotherapy APCEDEN®. Although other immunotherapies such as immune-check point inhibitors were also an available option, the poor performance status of the patient coupled with compromised mobility didn't qualify for these drugs to be chosen. With negligible side effects associated with APCEDEN® due to its *autologous* nature and its due approval by the Indian FDA for use in refractory cases of multiple indications with CA prostrate being one of them, APCEDEN® treatment was initiated.

RESULTS: The present study indicated that APCEDEN® was completely safe and suggestively effective to treat metastatic prostate cancer, as revealed by the post therapy follow up PET CT scan. The Neutrophil Lymphocyte Ratio (NLR) and Platelet Lymphocyte Ratio (PLR) showed an early sharp reduction within 1-month post therapy. The efficacy of APCEDEN® and the immune response of the patient was further investigated by expression of Treg and intracellular IFN-γ.

A substantial decrease was observed in Treg post treatment. On the contrary, a reverse correlation was observed with IFN-γ levels, which were induced post treatment with APCEDEN® **(Figure 2)**.

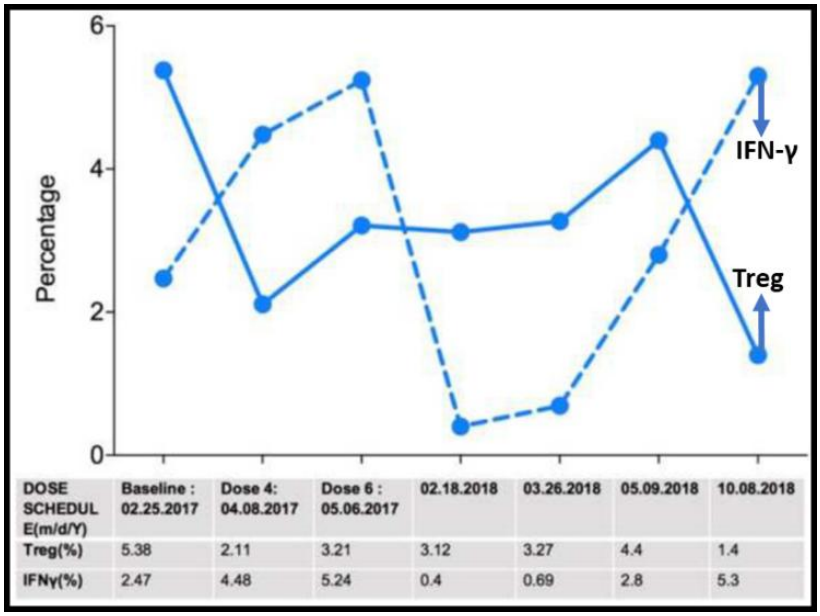

DOSE SCHEDULE(m/d/Y)	Baseline : 02.25.2017	Dose 4: 04.08.2017	Dose 6 : 05.06.2017	02.18.2018	03.26.2018	05.09.2018	10.08.2018
Treg(%)	5.38	2.11	3.21	3.12	3.27	4.4	1.4
IFNγ(%)	2.47	4.48	5.24	0.4	0.69	2.8	5.3

Figure 2: *Chart depicting patient's Treg and IFNg levels during the treatment.*

Complete remission of cancer was achieved with APCEDEN® **(Figure 3)** and the patient is still alive. The patient has responded well to immunotherapy (APCEDEN) second time in a row; as he suffered from kidney cancer 21 years ago. Furthermore, a significant improvement in his quality of life and appetite is quite evident.

The study once again highlights the safety and efficacy of APCEDEN, a completely customized cancer vaccine with great potential for treatment of advanced prostrate carcinoma. A lot of recent studies are now focusing on a "combinatorial approach" for treating prostrate carcinoma using both check-point inhibitors as well as dendritic cell based immunotherapies to enhance the overall survival of advanced prostate cancer patients.

Figure 3: *Comparison of PET-CT scan of the patient on 03/14/2017 before APCEDEN® therapy with PET-CT scans done on 06/09/2017 post APCEDEN® therapy and 07/18/2018 approx. 13 months after last dose of APCEDEN®.* ***A-C:*** *PET scan images of the pelvis region displaying reduced PSMA uptake and shrinkage in lesions post APCEDEN® treatment.* ***D-F:*** *PET scan images of the skeletal region showing reduced and dispersed PSMA avid sclerotic lesions at the both the time points respectively post APCEDEN® treatment.* ***G-I:*** *Full body PET scan images demonstrating a substantial tumor regression of metastatic lesions.*